

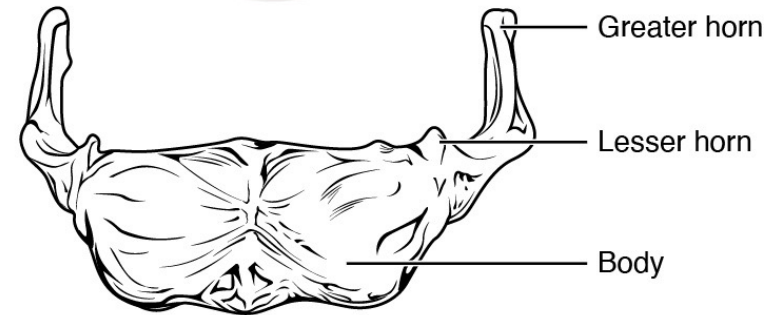
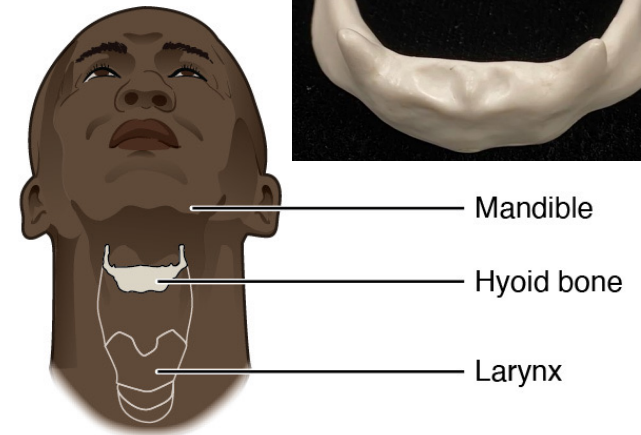
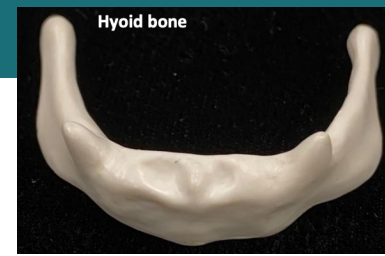
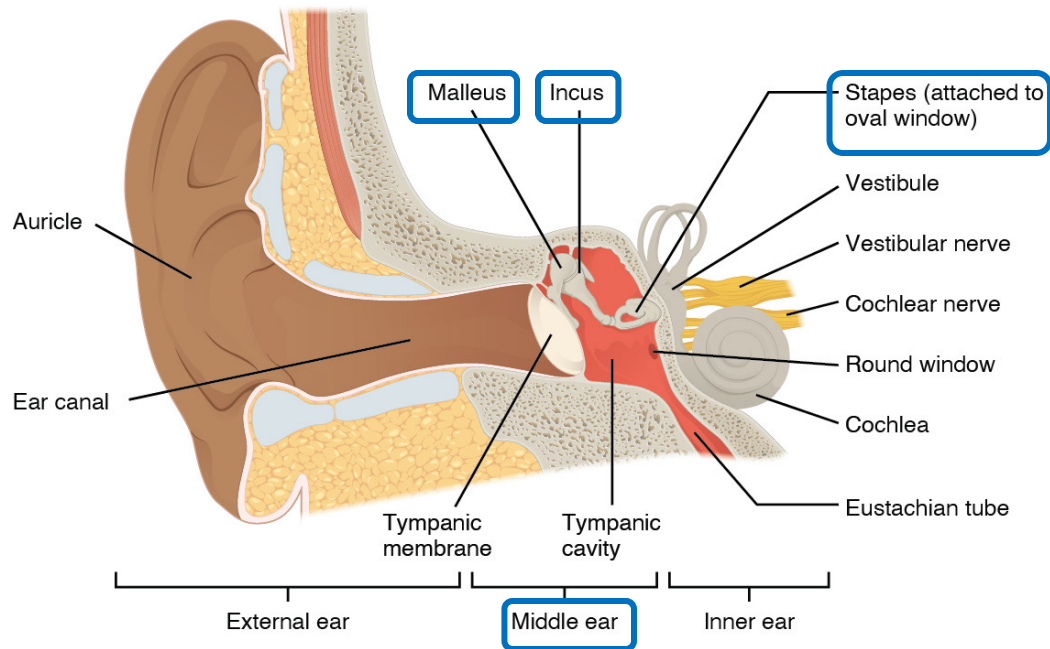
Module 5 LO5

Associated Bones

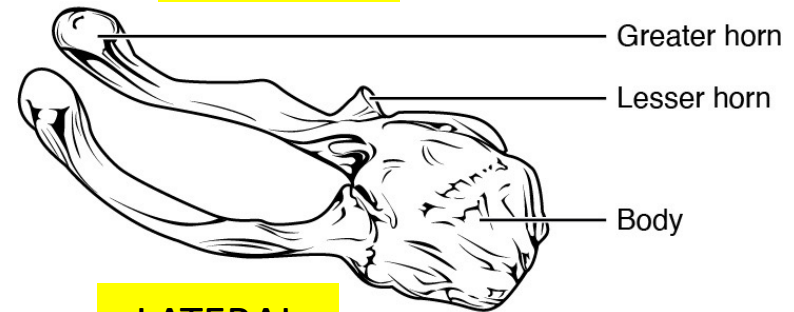
Dr. Lisa Brinn

lbrinn@fiu.edu

5. Associated Bones



ANTERIOR



LATERAL